

## Injuries to the Ulnar Collateral Ligament of the Thumb Metacarpophalangeal Joint

*Philip Heyman, MD*

### Abstract

*Injuries to the ulnar collateral ligament of the metacarpophalangeal (MCP) joint of the thumb are relatively common. When an incomplete rupture is present, valgus stress testing with the MCP joint positioned in extension reveals minimal or no instability (less than 30 degrees of laxity or less than 15 degrees more laxity than in the noninjured thumb). When a complete rupture is present, valgus stress testing with the MCP joint positioned in extension reveals marked laxity (more than 30 degrees or more than 15 degrees more laxity than in the noninjured thumb). In this instance, displacement of the ligament proximal and superficial to the adductor aponeurosis, which is often termed a Stener lesion, is likely. Partial ligament injuries in which the ligament is not displaced may be treated nonoperatively. When a Stener lesion is present, however, primary ligament healing cannot occur without operative management. Whether treatment should be operative or nonoperative can generally be decided on the basis of the findings from the history, the radiographs, and the physical examination, which should include valgus stress testing.*

**J Am Acad Orthop Surg 1997;5:224-229**

In 1955, Campbell<sup>1</sup> described the clinical signs and symptoms of ulnar collateral ligament insufficiency of the metacarpophalangeal (MCP) joint of the thumb, calling it "gamekeeper's thumb" because it was a frequent occupational injury of Scottish gamekeepers. The term described a chronic attritional injury resulting in instability, accompanied by pain and weakness of pinch and grasp.

Today, the practicing orthopaedist usually sees valgus instability of the thumb MCP joint that has been caused by an acute injury. Because the injury is commonly caused by a skiing accident, it is now often referred to as "skier's thumb." However, any severe valgus force on the abducted thumb

can injure the ulnar collateral ligament. Because stability of the thumb is important for prehension, treatment is directed toward optimizing ligament healing in order to restore full function.

### Anatomy and Biomechanics

The MCP joint is a diarthrodial joint that is primarily involved in flexion and extension, but which also allows some rotation, abduction, and adduction. Joint stability is provided by static restraints and dynamic stabilizers.

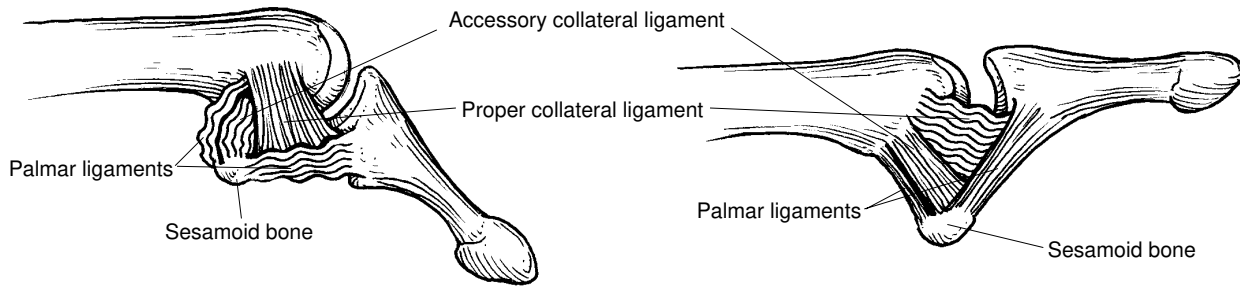
The static restraints of the MCP joint are the proper collateral ligament, the accessory collateral liga-

ment, the palmar plate, and, to a limited extent, the dorsal capsule. Biomechanical and clinical studies have shown that each of these structures contributes to joint stability and that their contribution is dependent on the position of the MCP joint.<sup>2,3</sup> In flexion, the taut proper collateral ligament, which runs from the middle of the metacarpal head to the palmar aspect of the proximal phalanx, is the primary joint stabilizer (Fig. 1). Because of this configuration, it also prevents palmar subluxation of the proximal phalanx. The dorsal capsule is also taut in flexion; however, it is relatively flimsy and thus much less important than the proper collateral ligament in stabilizing the flexed joint. In addition, because of its redundancy, the dorsal capsule does not play an important role in preventing palmar subluxation of the proximal phalanx. The accessory collateral ligament is palmar to and contiguous

*Dr. Heyman is in private practice with Hand Surgery Associates, PC, Denver.*

*Reprint requests: Dr. Heyman, Hand Surgery Associates, PC, Suite 500, Porter Medical Plaza, 2535 South Downing, Denver, CO 80210.*

*Copyright 1997 by the American Academy of Orthopaedic Surgeons.*



**Fig. 1** Left, In flexion, the proper collateral ligament and the dorsal capsule are tight. Right, In extension, the proper collateral ligament and the dorsal capsule are loose, and the accessory collateral ligament and palmar plate are tight.

with the proper collateral ligament. It extends palmarward and attaches to the volar plate.

In extension, the accessory collateral ligament and the palmar plate are taut and are the primary joint stabilizers against valgus stress.<sup>2,3</sup> When a traumatic valgus force is applied to the thumb MCP joint, the proper collateral ligament, the accessory collateral ligament, and the palmar plate provide joint stability when the dynamic stabilizers are overcome.<sup>2-4</sup>

The dynamic stabilizers include the thumb extrinsic muscles (extensor pollicis longus, extensor pollicis brevis, and flexor pollicis longus) and intrinsic muscles (abductor pollicis brevis, flexor pollicis brevis, and adductor pollicis). The adductor mechanism is of particular importance as a dynamic stabilizer.<sup>5</sup> It inserts into the extensor expansion through its aponeurosis, which lies superficial to the joint capsule and the ulnar collateral ligament. The adductor also has a deep insertion into the palmar aspect of the proximal phalanx by way of the ulnar sesamoid.

There is considerable variation in the range of flexion and extension of the thumb MCP joint. Some normal joints demonstrate as little as 5 degrees of motion, while others have a range of as much as 115 degrees.<sup>6,7</sup> The normal MCP

joint may hyperextend, or it may lack full extension. The amount of valgus laxity is also variable in normal thumbs. In full extension, valgus laxity averages 6 degrees. Valgus laxity increases to an average of 12 degrees when the joint is positioned in 15 degrees of flexion.<sup>6,7</sup>

### Mechanism of Injury

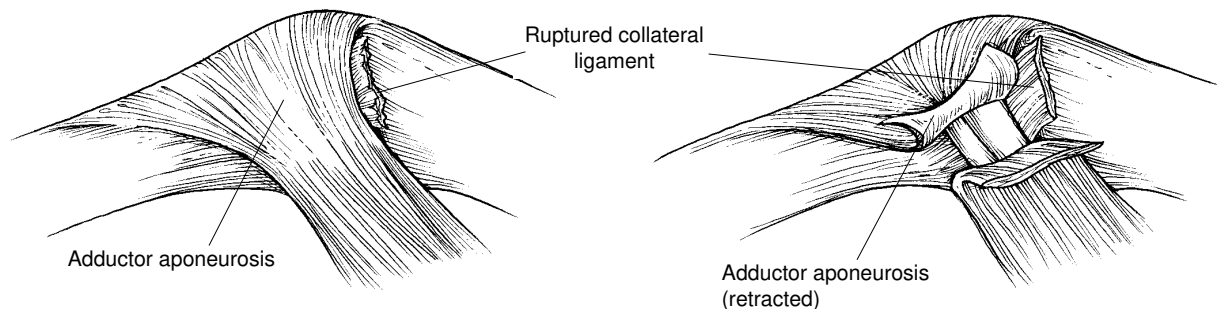
Any extreme valgus stress to the thumb can result in ligamentous disruption. The most common mechanism is a fall on the abducted thumb. In skiing, it has long been thought that the ski pole plays an important role in the pathogenesis of this injury. In the 1960s, most ski-pole handles had a strap that passed between the thumb and the index finger and wrapped around the wrist. With increased awareness of this injury, many new grip designs were subsequently developed. These include strapless grips with molded hand pieces, with or without a platform for the hand. However, newer design modifications have not had any detectable effect on preventing this injury.<sup>8</sup> Some have suggested that the ski pole prevents adduction of the thumb, which normally occurs during a fall, thus making the thumb more exposed to injury.<sup>9</sup>

### Pathologic Anatomy

A wide spectrum of pathologic disorders have been reported after acute valgus injuries to the thumb MCP joint. There may be rupture of the dorsal capsule, adductor mechanism, and extensor pollicis brevis.<sup>10</sup> Anatomic, biomechanical, and clinical studies have shown that when the injury is limited to these structures, the thumb will be stable on valgus stress testing.<sup>3</sup> More severe injuries involve rupture of the proper collateral ligament.

When the proper collateral ligament is ruptured, instability will be present when the thumb is tested in flexion.<sup>4</sup> When the accessory collateral ligament is also torn, the tear is considered complete, and there is instability in extension as well as flexion.<sup>3</sup> Rupture of the ulnar collateral ligament is typically at its distal insertion site on the base of the proximal phalanx. Occasionally, however, the rupture is in the midsubstance or more proximal.<sup>4,6,9</sup>

Displacement of the distal end of the completely ruptured ligament can occur such that it comes to lie superficial and proximal to the adductor aponeurosis (Fig. 2). This pathologic entity was first described by Stener in his classic paper in 1962.<sup>4</sup> There is general



**Fig. 2** Left, When a complete rupture of the ulnar collateral ligament is present, the distal end of the torn ligament is usually displaced proximal and superficial to the proximal edge of the intact adductor aponeurosis. Right, Division of the adductor aponeurosis is required for repair of the ligament.

agreement that, due to the interposition of the adductor aponeurosis, these injuries do not heal with non-operative treatment. Because the proper collateral ligament is anatomically contiguous with the accessory collateral ligament along their common edge, isolated proper collateral ligament tears are prevented from complete displacement by the intact accessory collateral ligament.<sup>3</sup>

Occasionally, radiographs will show an avulsion fracture from the ulnar aspect of the base of the proximal phalanx (Fig. 3). This fragment may be a small fleck or may be of substantial size.<sup>4,10</sup> Active contraction of the adductor at the time of injury has been implicated in the pathogenesis of this injury.<sup>11</sup> Avulsion fractures may be displaced or nondisplaced. The presence of a nondisplaced avulsion fracture does not rule out a complete ligament rupture. Conversely, there are cases in which the avulsion fracture is displaced and rotated and the ulnar collateral ligament is intact or only partially ruptured.

Lateral radiographs may show palmar subluxation of the proximal phalanx. This finding suggests extensive ligamentous disruption.<sup>10</sup> Radial subluxation is occasionally

seen on the posteroanterior view, which is highly indicative of a complete rupture. However, in most cases of partial or complete ligament ruptures, plain films appear normal.

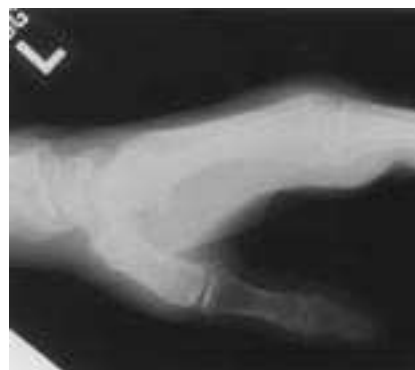### Evaluation

Patients with suspected ulnar collateral ligament injuries will present with a history of valgus injury followed by pain and swelling on the ulnar aspect of the MCP joint. Ecchymosis is frequently seen as well. Palpation of the ulnar aspect of the joint may reveal a lump. This finding represents the distal end of the displaced ligament and is highly suggestive of a Stener lesion.<sup>3,4,12</sup> However, lack of a mass does not rule out a Stener lesion.<sup>3</sup> Before valgus stress testing, radiographs should be obtained. In some cases in which an ulnar collateral ligament rupture is suspected, the films will show a fracture of the thumb metacarpal or the shaft of the proximal phalanx. Valgus stress testing is contraindicated in these cases.

After assessment with posteroanterior and lateral plain radiographs, valgus stress testing should be carried out. Acutely injured

patients will usually demonstrate guarding; therefore, local anesthetic should be infiltrated into the ulnar aspect of the joint before stress testing. Some authors suggest a median and/or ulnar nerve block at the wrist to negate the stabilizing effect of the intrinsic muscles.<sup>5</sup> However, if pain is relieved by an injection into the joint alone, these nerve blocks are not necessary.

The integrity of the proper collateral ligament is then assessed by carrying out valgus stress testing with the MCP joint in 30 degrees of



**Fig. 3** Avulsion fracture sustained by a 45-year-old man. The MCP joint was stable on valgus stress testing. After immobilization for 4 weeks, the thumb was painless and stable.

flexion. To avoid a false interpretation, the examiner must prevent MCP rotation by grasping the thumb proximal to the joint. If there is more than 30 degrees of laxity (or 15 degrees more laxity than on the noninjured side), rupture of the proper collateral ligament is likely. The thumb is then positioned in extension for repeat valgus stress testing. If valgus laxity is less than 30 degrees (or 15 degrees less than on the noninjured side), the accessory collateral ligament is intact. Because the accessory collateral ligament is contiguous with the proper collateral ligament, the intact accessory collateral ligament will prevent complete displacement of the proper collateral ligament, precluding a Stener lesion. If valgus laxity is greater than 30 degrees (or 15 degrees more than on the noninjured side), the accessory collateral ligament is also ruptured. In these complete ruptures, ligament displacement (i.e., a Stener lesion) is more than 80% likely.<sup>3</sup>

The examining orthopaedist may be concerned about valgus stress testing in cases in which there is a nondisplaced avulsion fracture; there may be fear of displacing a nondisplaced ligament rupture. Valgus stress testing should be performed regardless of whether such an avulsion fracture is present. In most instances, the mechanism of injury is a fall; if ligament displacement does not occur at the time of such an extreme or violent uncontrolled injury, stressing the joint under controlled circumstances should not cause ligament displacement.

Other techniques have been recommended for evaluation of these injuries, such as stress radiography, arthrography, and magnetic resonance imaging. In my opinion, these tests add unnecessary cost and provide little additional infor-

mation to that which can be obtained by an accurate physical examination.

### Recommended Treatment Algorithm

When a joint is stable when tested in flexion, the ligament is only partially ruptured, and a Stener lesion is not present. Ligament healing will occur by nonoperative means. A period of immobilization in a short arm-thumb spica cast for 4 weeks is appropriate. The interphalangeal joint may be left free if the cast is otherwise well molded. In some cases, a hand-based cast or a splint made of heat-molded plastic can be used. Treatment for these less severe injuries can be tailored to the patient's needs, according to the surgeon's judgment. After the period of immobilization, active and passive range of motion can be started. Grip strengthening can begin by the sixth week.

In the thumb is unstable in extension (more than 30 degrees of laxity or 15 or more degrees of laxity than on the noninjured side), a complete rupture is present, and ligament displacement is likely.<sup>3</sup> Operative management is necessary in this setting.

### Surgical Technique

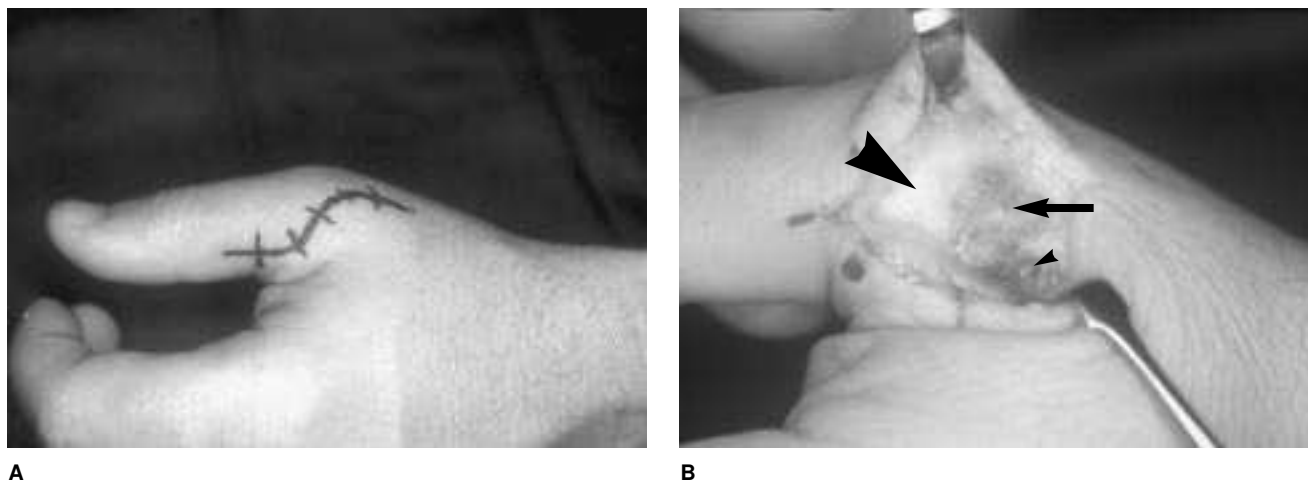
Surgical repair can be carried out with use of a regional anesthetic (axillary block or Bier block) and tourniquet control. A chevron or S-shaped incision is used (Fig. 4, A). The radial sensory nerve branches are isolated and protected. Beneath the subcutaneous tissue and a layer of loose adventitia, the proximal edge of the adductor aponeurosis is identified. If the ligament is ruptured and displaced, its distal end will be seen in cross

section, held in the displaced position by the proximal edge of the adductor aponeurosis (Fig. 4, B).

The adductor aponeurosis is then incised longitudinally, parallel and just palmar to the extensor pollicis longus tendon. The adductor aponeurosis is retracted distally and the dorsal capsule, which is frequently torn, is inspected, after which the proper collateral ligament and the accessory collateral ligaments are assessed.

If palmar subluxation was seen on the preoperative radiographs, or if the surgeon believes soft-tissue repair will not hold the joint in a reduced position, joint reduction and pinning should be carried out. A smooth 0.045-inch Kirschner wire is passed antegrade through the base of the proximal phalanx and out through the skin on the radial side of the thumb. The joint is then held in a reduced or slightly overreduced position in 15 degrees of flexion, and the wire is passed retrograde across the joint. Fluoroscopy can be used to confirm that the joint is well positioned.

The collateral ligament is then repaired. In the rare case of a mid-substance tear, a direct repair may be carried out with absorbable 4-0 suture material. If there is a small fragment of bone associated with the avulsed ligament, this should be excised. A larger fragment should be preserved. A number of techniques for repairing the ligament, with or without an associated avulsion fracture, have been described. Many advocate use of a transosseous suture of stainless-steel wire or other nonabsorbable suture material.<sup>9,10,12</sup> The suture may be tied over a button on the radial side of the MCP joint with a pullout suture technique.<sup>9,10</sup> Alternatively, the suture can be tied directly over bone on the proximal phalanx to achieve a tighter repair, leaving no exposed suture. Some



**Fig. 4** A, Recommended S-shaped skin incision for surgical repair. B, Surgical exposure reveals a Stener lesion (arrow). Large arrowhead indicates the adductor aponeurosis; small arrowhead indicates edematous end of ruptured ligament.

researchers have reported good results after sewing the ligament to the periosteal tissues at the base of the proximal phalanx.<sup>4,11,13,14</sup> In my opinion, the particular suture technique employed is not of importance provided the soft-tissue repair is anatomic and the orientation of the ligament is restored. The proper collateral ligament should be secured to its normal insertion site on the palmar and ulnar aspect of the base of the proximal phalanx. The ulnar corner of the palmar plate may also need reattachment. Subsequently, the accessory collateral ligament is sewn to the palmar plate volarly and distally. The dorsal capsule is then sutured. The adductor aponeurosis should be repaired with an absorbable suture.

After skin closure, a thumb spica splint is applied. Care should be taken to mold it well about the MCP joint so that the interphalangeal joint can be left free. Motion of the interphalangeal joint is encouraged in the postoperative period to prevent extensor tendon adhesions and stiffness. The cast and pin are removed after 4 weeks,

and active MCP joint motion is begun. A hand-based splint immobilizing the MCP joint is applied at the time of cast removal and is maintained for 2 weeks. Unrestricted usage is allowed at 3 months.

### Results

Accurate early diagnosis is one of the most important factors determining functional outcome. In thumbs with partial ligament injuries, nonoperative treatment by immobilization will yield a stable painless thumb with near-normal motion in the vast majority of cases. In thumbs with a complete rupture treated operatively within 3 weeks of the injury, a good to excellent result can be expected in more than 90% of cases, regardless of the technique of ligament repair.<sup>9,10,15,16</sup> Pain and stiffness can be expected to be mild or absent, and pinch and grip strength will be near normal. The rate of return to former activities, including recreational sports, has been reported to be as high as 96%.<sup>9</sup>

### Complications

Even if the radial sensory nerve is isolated and protected during the procedure, a neurapraxia may ensue. This usually resolves spontaneously. Stiffness of the MCP joint and interphalangeal joint frequently occurs, but is usually not a functional problem and tends to improve with time.

A more troublesome complication is persistent instability. This outcome is uncommon,<sup>9,17</sup> but may occur despite a technically good repair. Chronic instability manifests itself clinically as pain during pinch and grasp as well as weakness. If chronic instability is left untreated, secondary arthritic changes may occur.

### Treatment of Chronic Instability

The most common causes of chronic instability of the thumb MCP joint after an acute rupture are failure of the patient to seek treatment and missed diagnosis. The longer an untreated complete rupture

exists, the less likely it is that an anatomic reconstruction will be successful.<sup>10,18</sup> Some surgeons have reported success with reconstruction employing the remaining capsuloligamentous tissues.<sup>13,14,19</sup> Others have reported good results with a delayed primary repair augmented by dynamic transfer of the adductor pollicis from the ulnar sesamoid to the base of the proximal phalanx.<sup>5</sup> Ligament reconstruction can also be carried out with a free tendon graft woven through the metacarpal neck and the base of the proximal phalanx.<sup>15,18</sup> In most cases, the palmaris longus is used, but when that is not available, the plantaris, a toe extensor, a slip of the abductor pollicis longus, or a portion of the flexor carpi radialis can be employed.<sup>17</sup>

In long-standing cases of ulnar collateral ligament instability, secondary arthritic changes may be seen. In this setting, arthrodesis should be strongly considered. Arthrodesis should also be considered for manual laborers. It should be noted that in some noninjured thumbs, a normal arc of motion may be as little as 5 degrees.<sup>6,7</sup> For this reason, arthrodesis does not lead to much impairment if motion of the interphalangeal joint and carpometacarpal joint is preserved.

### Summary

Successful management of acute injuries of the ulnar collateral ligament of the thumb MCP joint prevents the sequelae of instability and pain. Nonoperative treatment

of partial ligament injuries with cast or splint immobilization will result in a stable and painless thumb. Valgus laxity greater than 30 degrees or more than 15 degrees more than in the noninjured thumb with the MCP joint in extension is an indication for operative management. Examination should be carried out with the use of local anesthetic. Stress testing should be carried out even if there is an avulsion fracture from the base of the proximal phalanx. The essential components of the surgical repair are anatomic reconstruction of the ulnar collateral ligament, palmar plate, and dorsal capsule, followed by protection in a cast or splint. The functional results of operative treatment are excellent, resulting in a stable and painless thumb in the vast majority of cases.

### References

- Campbell CS: Gamekeeper's thumb. *J Bone Joint Surg Br* 1955;37:148-149.
- Minami A, An KN, Cooney WP III, Linscheid RL, Chao EYS: Ligamentous structures of the metacarpophalangeal joint: A quantitative anatomic study. *J Orthop Res* 1984;1:361-368.
- Heyman P, Gelberman RH, Duncan K, Hipp JA: Injuries of the ulnar collateral ligament of the thumb metacarpophalangeal joint: Biomechanical and prospective clinical studies on the usefulness of valgus stress testing. *Clin Orthop* 1993;292:165-171.
- Stener B: Displacement of the ruptured ulnar collateral ligament of the metacarpophalangeal joint of the thumb: A clinical and anatomical study. *J Bone Joint Surg Br* 1962;44:869-879.
- Neviaser RJ, Wilson JN, Lievano A: Rupture of the ulnar collateral ligament of the thumb (gamekeeper's thumb): Correction by dynamic repair. *J Bone Joint Surg Am* 1971;53:1357-1364.
- Palmer AK, Louis DS: Assessing ulnar instability of the metacarpophalangeal joint of the thumb. *J Hand Surg [Am]* 1978;3:542-546.
- Coonrad RW, Goldner JL: A study of the pathological findings and treatment in soft-tissue injury of the thumb metacarpophalangeal joint: With a clinical study of the normal range of motion in one thousand thumbs and a study of post mortem findings of ligamentous structures in relation to function. *J Bone Joint Surg Am* 1968;50:439-451.
- Carr D, Johnson RJ, Pope MH: Upper extremity injuries in skiing. *Am J Sports Med* 1981;9:378-383.
- Derkash RS, Matyas JR, Weaver JK, et al: Acute surgical repair of the skier's thumb. *Clin Orthop* 1987;216:29-33.
- Smith RJ: Post-traumatic instability of the metacarpophalangeal joint of the thumb. *J Bone Joint Surg Am* 1977;59:14-21.
- Smith MA: The mechanism of acute ulnar instability of the metacarpophalangeal joint of the thumb. *Hand* 1980;12:225-230.
- Abrahamsson SO, Sollerman C, Lundborg G, Larsson J, Egund N: Diagnosis of displaced ulnar collateral ligament of the metacarpophalangeal joint of the thumb. *J Hand Surg [Am]* 1990;15:457-460.
- Kaplan EB: The pathology and treatment of radial subluxation of the thumb with ulnar displacement of the head of the first metacarpal. *J Bone Joint Surg Am* 1961;43:541-546.
- Strandell G: Total rupture of the ulnar collateral ligament of the metacarpophalangeal joint of the thumb: Results of surgery in 35 cases. *Acta Chir Scand* 1959;118:72-80.
- Gerber C, Senn E, Matter P: Skier's thumb: Surgical treatment of recent injuries to the ulnar collateral ligament of the thumb's metacarpophalangeal joint. *Am J Sports Med* 1981;9:171-177.
- Saetta JP, Phair IC, Quinton DN: Ulnar collateral ligament repair of the metacarpophalangeal joint of the thumb: A study comparing two methods of repair. *J Hand Surg [Br]* 1992;17:160-163.
- Glickel SZ, Malerich M, Pearce SM, Littler JW: Ligament replacement for chronic instability of the ulnar collateral ligament of the metacarpophalangeal joint of the thumb. *J Hand Surg [Am]* 1993;18:930-941.
- Helm RH: Hand function after injuries to the collateral ligaments of the metacarpophalangeal joint of the thumb. *J Hand Surg [Br]* 1987;12:252-255.
- Isani A, Melone CP Jr: Ligamentous injuries of the hand in athletes. *Clin Sports Med* 1986;5:757-772.