

Wrist Fractures

What is a wrist fracture?

The wrist is made up of eight small bones and the two forearm bones, the radius and ulna (see Figure 1). The shape of the bones allows the wrist to bend and straighten, move side-to-side, and rotate, as in twisting the palm up or down. A fracture may occur in any of these bones when enough force is applied, such as when falling down onto an outstretched hand. Severe injuries may occur from a more forceful injury, such as a car accident or a fall off a roof or ladder. Osteoporosis, a common condition in which the bone becomes more brittle, may make one more susceptible to getting a wrist fracture.

The most commonly broken bone of the wrist is the radius (see Figure 1). Many people think that a fracture is different from a break, but they are the same. When the wrist is broken, there is pain, swelling, and decreased use of the hand and wrist. Often the wrist appears crooked and deformed. Fractures of the small wrist bones, such as the scaphoid, are unlikely to appear deformed (see Figure 1). Fractures may be simple with the bone pieces aligned and stable. Other fractures are unstable and the bone fragments tend to displace or shift, in which case the wrist is more likely to appear crooked. Some fractures break the normally smooth, ball bearing-like joint surface; others will be near the joint but leave the joint surface intact. Sometimes the bone is shattered into many pieces, which usually makes it unstable. An open (compound) fracture occurs when a bone fragment breaks through the skin. There is some risk of infection with compound fractures.

How are they evaluated?

Examination and x-rays are needed so that your doctor can tell if there is a fracture and to help determine the treatment. Sometimes a CT scan or MRI may be used to get better detail of the fracture fragments and associated injuries. In addition to the bone, ligaments (the structures that hold the bones together), tendons, muscles, and nerves may be injured as well when the wrist is broken. These injuries may need to be treated in addition to the fracture.

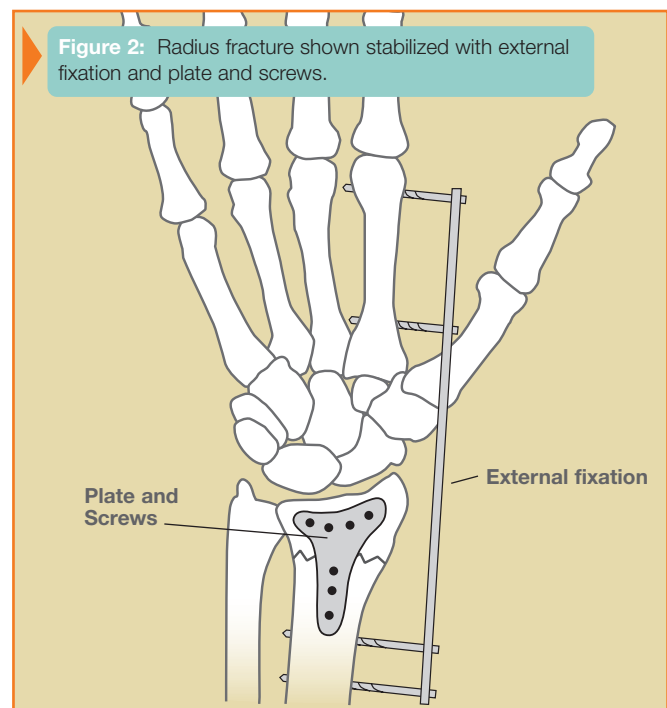
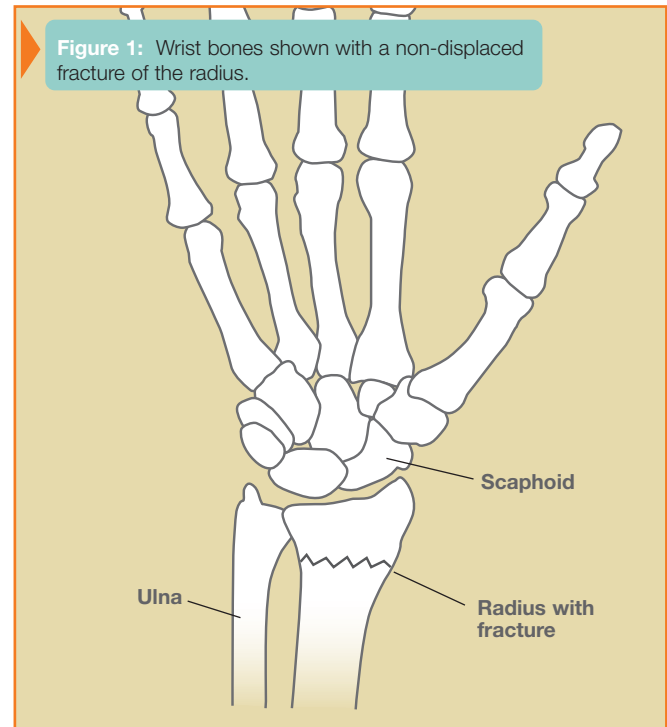
How are they treated?

The pattern of the fracture, whether it is displaced or non-displaced, and whether it is stable or unstable are all factors in determining the treatment. Other important considerations include your age, overall health, hand dominance, work and leisure activities, the presence of any prior injury or arthritis, and any associated injuries.

A splint or cast may be used to treat a fracture that is not displaced, or to protect a fracture that has been set. Other fractures may need surgery to properly set the bone and/or to stabilize it. Fractures may be stabilized with pins, screws, plates, rods, or external fixation (see Figure 2). External fixation is a method in which a frame outside the body is attached to pins which have been placed in the bone above and below the fracture site, in effect keeping it in traction until the bone heals. Sometimes arthroscopy is used in the evaluation and treatment of wrist fractures. Your hand surgeon will determine as to which treatment is the most appropriate in your individual case.

On occasion, bone may be missing or may be so severely crushed that there is a gap in the bone once it has been re-aligned. In such cases, a bone graft may be necessary. In this procedure, bone is taken from another part of the body to help fill in the defect. Bone from a bone bank or synthetic bone graft substitutes may also be used.

While the wrist fracture is healing, it is very important to keep the fingers flexible, provided that there are no other injuries that would require that the fingers be immobilized. Otherwise, the fingers will become stiff, hindering the recovery of hand function. Once the wrist has enough stability, motion exercises may be started for the wrist itself. Your hand surgeon will determine the appropriate timing for these exercises. Hand therapy is often used to help recover flexibility, strength, and function.



What kind of results can I expect?

Recovery time varies considerably, depending on the severity of the injury, associated injuries, and other factors as noted previously. It is not unusual for maximal recovery from a wrist fracture to take several months. Some patients may have residual stiffness or aching. If the surface of the joint was badly injured, arthritis may develop. On occasion, additional treatment or reconstructive surgery may be needed.